



AYURVEDIC MANAGEMENT OF DUSHTA VRANA -A CASE STUDY

Dr.Poornima Rajole¹, Dr. Ajaykumar Acharya²

¹2nd Yr PG Scholar, Department of Kayachikitsa, AAMC, Tumkuru-572105

²Assistant Professor, Department of Kayachikitsa, AAMC, Tumkuru-572105

ABSTRACT

Dushtavrana (non-healing ulcer) is a prevalent issue in contemporary times, often arising as a complication of trauma or pathological insult, leading to prolonged suffering for the patient physically as well as mentally. Ulcer is discontinuity often excavation of skin exhibiting loss of epidermis and portion of dermis and even subcutaneous fat. In Ayurveda, "Vrana" refers to wounds or ulcers, and the term "Dustavrana" describes chronic or non-healing ulcers that have become complicated. Dustavrana can be characterized by features such as inflammation, pus formation, and prolonged healing times. Non-healing ulcers can be challenging to manage, and Ayurvedic remedies offer a holistic approach that emphasizes the balance of body, mind, and spirit. Research into Ayurvedic treatments often focuses on herbal formulations, dietary adjustments, and lifestyle modifications.

KEYWORDS: *Dushtavrana, non-healing ulcer,*

INTRODUCTION

The *vrana* (wound) and *ropana* (healing) are the two sides of the surgical coin in which an expert surgeon has to play role his role sincerely. The wound *Vrana* is imitative from the verbal root *Vrana* which means anything that causing discontinuity of the skin and other tissues under lying it¹. Means splitting or tearing of the body tissues, since it causes discontinuity of the body. The scars of the wound never disappear even after healing and remains till the body survives is called *vrana* (wound) by the wise².

Detailed description about *vrana* (wound) is mentioned by *Acharya Sushruta*. *Vrana*(wound) is generally classified into two groups i.e *Shareera and Agantuja* are due to vitiated dosha and *Sadhyo Vrana* (wound) which is caused due to trauma³. If the *vrana* (wound) gets infective or not to heal for a long time then it is called as *Dushtavrana* (infected wound or non-healing ulcer)⁴.

Ulcer is a discontinuity, often excavation of skin exhibiting loss of epidermis and portion of the dermis and even sub-cutaneous fat. Despite that fact that wound healing is a natural process it is influenced by systemic factors like microorganism, growth factor, vascularity and debris. The management of *Dushta Vrana* has been described in various Ayurvedic texts.

CASE REPORT

A male patient aged about 22 years visited in Kayachikitsa OPD of Ashwini Ayurvedic Medical College and Research Centre, Tumkuru, Karnatakaka (OPD.Reg.No.18681 and date 03/07/2024) Presenting with complaints of ulceration on dorsum of foot in left side, itching and discoloration since 3 years.

ASSOCIATED COMPLAINTS

Patient complaining of disturbed sleep, redness, itching and discoloration

HISTORY OF PRESENT ILLNESS

Patient was normal 3 years ago gradually he developed itching sensation over the foot with pus discharge he went to allopathy hospital & after the treatment he got mild symptomatic relief. Again, the patient developed blackish discoloration and pain with pus discharge the symptoms didn't relapse he underwent the allopathic treatment and took the medications, but it relapses again he left the treatment in between with a frustration and didn't undergo any treatment. Due to the unsatisfaction and frustration the patient visited our hospital AAMC for further treatment. He was diagnosed as *Pitta Kaphaja Dushta Vrana & treated on the line of management of Dushta Vrana with Pitta Kapha Shamana*.

PAST HISTORY

Patient is N/H/O Diabetes Milletus, HTN, Dyslipidemia

FAMILY HISTORY

Nothing significant all are said to be healthy in his family

PERSONAL HISTORY

Diet – Mixed

Appetite – Regular

Sleep – Disturbed

Bowels – Normal (two times a day)

Micturition – Normal (3-4 times a day)

Habits – Tea

Addiction – None



GENERAL EXAMINATION

Blood pressure	120/80 mmHg
Respiratory rate	18/bpm
Edema	Absent
Icterus	Absent
Pulse rate	84/min
Height	5 feet 9 inches
Weight	110/bpm
Nails	Normal
Lymph nodes	Normal
Heart rate	72/bpm
Pallor	Absent
Cyanosis	Absent
Temperature	36°C

DASHAVIDHA PARIKSHA

<i>Dashavidha Pariksha</i>	<i>Interpretations</i>
<i>Prakruti</i>	<i>Kapha Vata</i>
<i>Vikruti</i>	<i>Pitta Kapha</i>
<i>Sara</i>	<i>Avara</i>
<i>Samhanana</i>	<i>Madhyama</i>
<i>Pramana</i>	<i>Madhyama</i>
<i>Satyma</i>	<i>Anushna sheeta</i>
<i>Satva</i>	<i>Madhyama</i>
<i>Vaya</i>	<i>Yuva</i>
<i>Ahara shakti</i>	<i>Madhyama</i>
<i>Vihara shakti</i>	<i>Madhyama</i>

ASTAVIDHA PARIKSHA

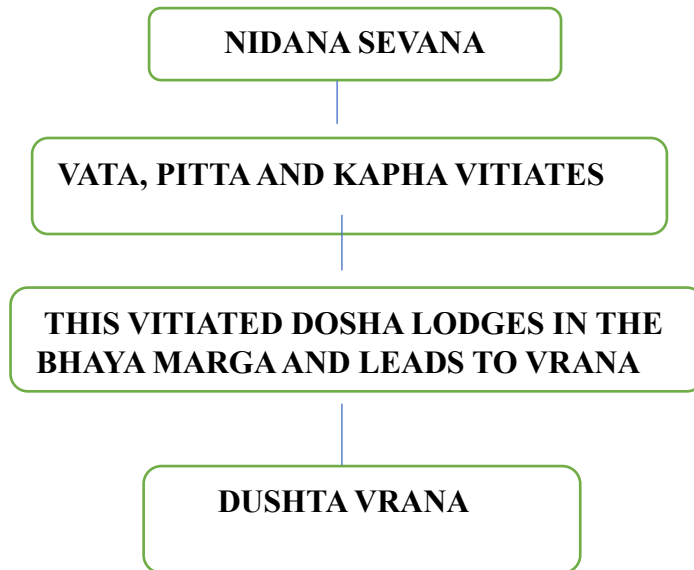
<i>Astavidha pariksha</i>	<i>Interpretations</i>
<i>Nadi</i>	<i>Kapha Vata</i>
<i>Mala</i>	<i>Prakruta</i>
<i>Mutra</i>	<i>Prakruta</i>
<i>Jiwha</i>	<i>Upalipta</i>
<i>Shabda</i>	<i>Prakruta</i>
<i>Sparsha</i>	<i>Ushna</i>
<i>Drik</i>	<i>Prakruta</i>
<i>Akruti</i>	<i>Sthula</i>

MATERIALS AND METHODS

Formulation of the proper and relevant line of treatment is the main entity in the wound management, which includes external and internal medications in the form of *Sodhana* and *Ropana* concept with relation to *Dushtavrana* (non healing ulcer)



SAMPRAPTI



CHIKITSA

The patient was treated with external application

Treatment procedure	From	To	Number of days
Cleaning of wound with <i>Panchavalkala kashaya</i> + betadine <i>Jatyadi taila</i> was applied and wound dressing with sterile gauze with gap of 2 days bandaging was done	03/07/24	15/07/24	12 days
Cleaning of wound with <i>Panchavalkala kashaya</i> with <i>jatyadi taila</i> and <i>tankana bhasma</i> was applied and wound dressing with sterile gauze with gap of 4 days bandaging was done	15/07/24	06/08/24	22 days

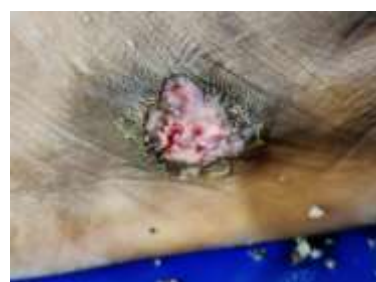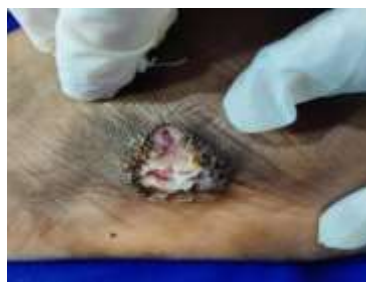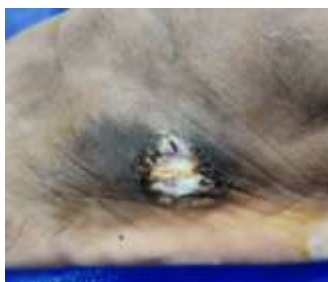DAYS	Shodhana	SHAMANA AUSHADHI
1 st day treatment 3-7-24 to 15-7-24	Dressing done	<i>Tab.Grab</i> <i>Tab.Arogyavardini vati</i> <i>Tab.Tiktamrita</i> <i>Panchavalkala kwatha churna</i>
1 st follow up 15-7-24 to 25-7-24	Dressing done	<i>Tab.Grab</i> <i>Tab.Arogyavardini vati</i> <i>Tab.Tiktamrita</i>
2 nd follow up 25-7-24 to 6-8-24	Dressing done	<i>Tab.Grab</i> <i>Tab.Gandhaka rasyana</i> <i>Tab.Tiktamrita</i>
3 rd follow up 6-8-24 to 21-8-24	Dressing done	<i>Tab.Grab</i> <i>Tab.Gandhaka rasyana</i> <i>Aragwadadi kashaya</i> <i>Elup nano cream</i>
4 th follow up 21-8-24 to 28-8-24	Dressing done	<i>Tab.Arogyavardini vati</i> <i>Manjishthadi kashaya</i> <i>Panchavalkala kashaya</i>



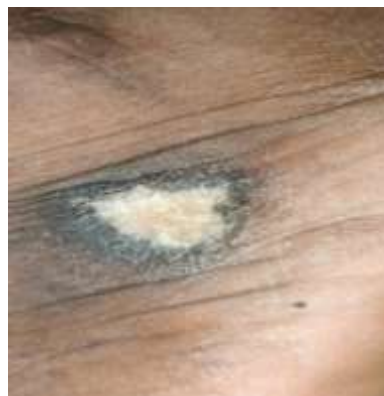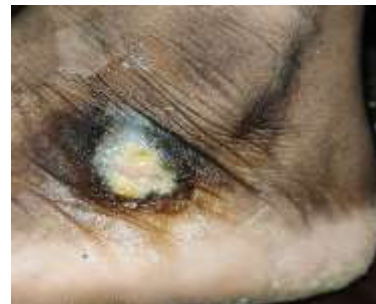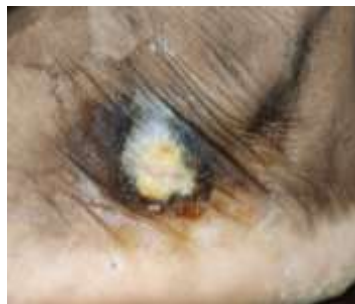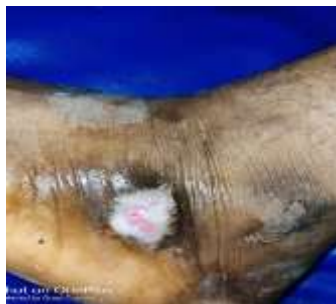BEFORE TREATMENT



DURING TREATMENT



AFTER TREATMENT





OBSERVATION TABLE

Parameters	Before treatment	During treatment	After treatment
Srava (Pus discharge)	Slight discharge	Mild discharge	Absent
Vrana (Granulation tissue)	Present	Present	Absent
Slough	Present	Present	Absent
Daha (Burning sensation)	Present	Present	Absent
Kandu (itching)	Present	Present	Absent
Redness	Slight Present	More redness	Absent
Ruja (Pain)	Present	Present	Absent
Varna(colour)	Blackish	Yellowish	Whitish
Patient is under treatment.....			

DISCUSSION

A three-year-old *Dushta Vrana* which is reluctant to heal even after proper management of wound by contemporary science, shown encouraging result by the ayurvedic medicine with 50 days. The probable mode of action of the internal medication can be drawn as below.

1. Tablet Grab composed of *Triphala Guggulu, Gandhaka Rasyana, Arogyavardini Rasa, Vranapahari Rasa, Guduchi, Manjistha* used to cure *Twak roga* and *Vrana* it prevents *Putighna* (foul smell), *Kandughna* (prevents itching) and acts as *Lekhana* (cleansing agent)

2. Capsule Tiktamrita composed of *Amrita, Vasa, Kantakari, Patola, Nimba, Triphala, Shudha Guggulu* given for curing the itching sensation and balances *Kapha* and *Pitta*

3. Manjishtadi Kashaya⁵ composed of ingredients like *Manjishta, Triphala, Tikta, Vacha, Daru, Nisha, Amruta and Nimba*. given for itching, *dadru, pama* and *rakta mandala* it's also called as *Raktashodhakarishtha* it helps in blood purification and detoxifying.

4. Aragwadadi Kashaya⁶ composed of *Aragwadha, Indrayava, Patola, Kakatiktika, Nimba, Amruta, Patha, Bhunimba, Saireyaka, karanja, Pootikaranja Aragwadha* has *Madhura rasa, Sheeta Veerya, Madhura Vipaka* it acts as *Kaphapittahara, Sramsana and Tridosahara* given for curing of *Medo Dosha* because the margin of wound is blackish colour. It reduces *Kapha dosha* and acts on the skin.

5. Gandhaka Rasayana⁷ composed of *Gandhaka rasayana, Guduchi, Haritaki, Amalaki, Vibhitaki, Shunti, Bhringaraja, Ardraka, Sita* given for blood purification allergies and pain symptoms.

6. Arogyavardini Vati⁸ composed of *Shudha Parada, Shudha Gandhaka, Loha Bhasma, Abhraka Bhasma, Tamra Bhasma, Haritaki, Vibhitaki, Amalaki, Shilajatu, Guggulu, Eranda, Katuki, Nimba* it balances *Kapha* and *Pitta Dosha* it has *Shothahara* (anti-inflammatory) properties it helps in *Shodhana* and balances all three *Doshas Vata, Pitta* and *Kapha*.

6. Raktashodhaka⁹ composed of *Nagarmotha, Ashwattha, Padmaka, Katuki*, given for *Vicharchika* (eczema) and *Kandughna* (itching)

7. Jatyadi taila¹⁰ composed of *Jati, Nimba, Patola, Sikta, Madhuka, Haridra, Daruharidra, Manjishta, Katurohini, Padmaka, Lodhra, Abhaya, Sariva, Naktamla beeja, Jatyadi taila* are having *shodhana, ropana* and *Vedana Sthaapana* properties, *Tikta, Katu, Kashaya Rasas* and *Ruksha, Laghu Gunas Kashaya Rasa* does *Shodhana* it might be helpful in

Vrana Ropana, Tikta Rasa does *Twak Mamsa Sthireekarana* and *Lekhana*.

8. Panchavalkala kwatha¹¹ composed of *Nyagrodha, Udumbara, Ashwatha, Parisha and Plaksha* it has *Shothahara* (anti-inflammatory) and antioxidant, antibacterial, antimicrobial wound purifying and healing, astringent properties, so by this the wound is cleaned.

9. Tankana Bhasma it has *Shodhana* properties.

10. Elup nano cream contains *Haridra, Mandukaparni, Daruharidra, Manjishta, Padma, Yashimadhu, Musta, Jati, Nimba, Patola, Karanja, Vata, Yashada Bhasma, Gandhaka* indicated in *Dushtavrana* and *Agantuja Vrana* it repairs and heals wound helps in collagen formation.

CONCLUSION

Most of the *Dushtavrana* are the result of vitiation of all 3 *doshas* one of the *dosha* dominance. The *Jatyadi taila* and *madhu* is mentioned for *vrana shodhana*. The combination of all the three i.e, *Jatyadi taila, Pachavalkala kwatha* and *Tankana Bhasma* has given the effect of both *shodhana* and *ropana* of the *vrana* within 50 days. Patient is advised for *Pathya Apathya* and also on internal medications.

REFERENCES

1. *Sushruta Samhita* translated by K.R. Sreekanthamurthy published by Chaukambha Orientalia, reprint edition, 2010; 2; *Chikitsa sthana 1st chapter 6th shloka no 4*
2. *Sushruta Samhita* translated by K.R. Sreekanthamurthy published by Chaukambha Orientalia, reprint edition, 2010; 2; *Chikitsa sthana 1st chapter 3, shloka no 3*
3. *Sri Ram Bhat M, SRBs Manual of surgery 5th edition, reprint edition, 2016; 1:7*
4. *S. Das, A concise textbook of surgery, 7th edition, reprint on, 2012; chapter 1st, Page 7,8*
5. *Bhaishajya Ratnavali of Kaviraj Govind Das Sen volume 2 edited by Bhisagratna Shri Brahmashankar Mishra commented by Shri Kaviraj Ambikadatta Shastri published by Chaukhamba Sanskrit Bhawan Varanasi edition first 2006; Chapter 47, page 758, shloka no 53*
6. *Bhaishajya Ratnavali of Kaviraj Govind Das Sen edited with Siddhiprada Hindi commentary by Prof. Siddhi Nandan Mishra published by Chaukhamba Surbharati Prakashan Varanasi edition 2015; Chapter 59, Page 866, shloka no 32/33*
7. *Bhaishajya Ratnavali of Kaviraj Govind Das Sen edited with Siddhiprada Hindi commentary by Prof. Siddhi Nandan Mishra published by Chaukhamba Surbharati Prakashan Varanasi edition 2015; Chapter 59, Page 927, shloka no 32*



8. *Bhaishajya Ratnavali of Kaviraj Govind Das Sen edited with Siddhiprada Hindi commentary by Prof.Siddhi Nandan Mishra published by Chaukhamba Surbharati Prakashan Varanasi edition 2015; Chapter 54, Page 871, shloka no111-117*
9. *Ayurveda Sara Sangraha Shri Vaidyanath Ayurveda Bhavan Limited Kolkata, Patna, Jhansi, Nagpur 2009 edition;Page 574.*
10. *Bhaishajya Ratnavali of Kaviraj Govind Das Sen edited with Siddhiprada Hindi commentary by Prof.Siddhi Nandan Mishra published by Chaukhamba Surbharati Prakashan Varanasi edition 2015; Chapter 47, Page 825-826, shloka no 62-66*
11. *Vyas Palak, Prajapati PK,Shukla VJ.A herbal wound healing gel . Earthjournals.org Voulme 3 Issue 2 2013:49-60. And Sakhitha et al: Formulation.Anti-Bacterial Activity and Wound Healing property of Panchavalkaladi Ointment. IAMJ:Volume 1;Issue 4;July-Aug 2013:1-5*